

Purpose

Gain a deeper anatomical understanding of the vertebral column and back musculature involved in:

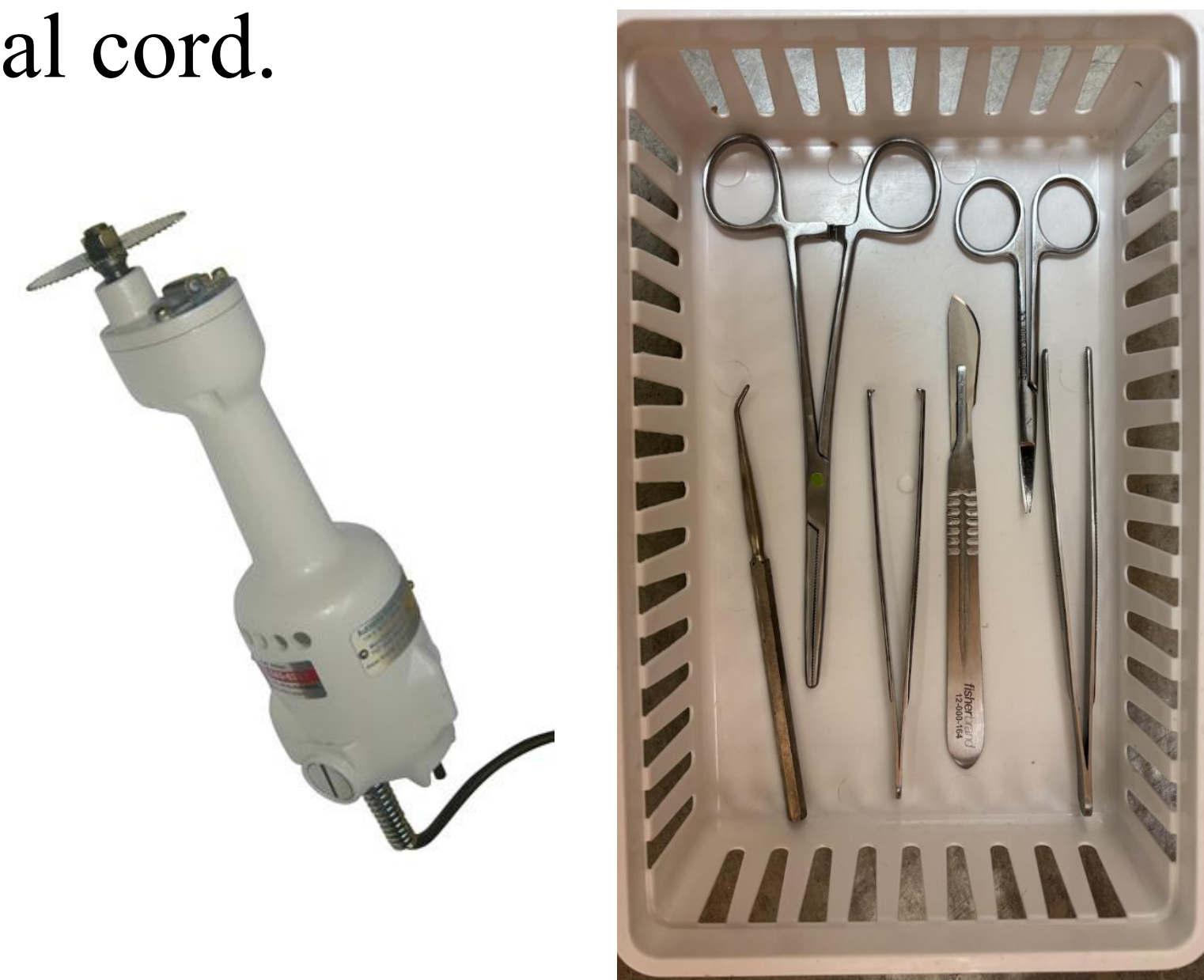- Structural changes associate with scoliosis
- Protection and function of the Central Nervous System
- Movement and gait mechanics

Methods

Cadaveric dissection: A complete laminectomy was performed, starting from superficial back musculature to deep to detach the spinal cord.

Tools:

- Surgical Scalpel and Scissor
- Hemostat and Forceps
- Stryker Saw
- Mallet and Chisel



Deep Back Musculature




Figure 1. Posterior view of the Erector Spinae Muscles.
The spinalis (A), longissimus (B) and iliocostalis (C) muscles.

The muscles of the deep back play a key function in protecting the spinal cord as well as in maintaining posture and controlling torso movement. This group of muscles perform torso extension, important for standing and bending.¹

Scoliosis



Figure 2. Deep View of the Back

The lumbar transverse processes can be seen following the curvature of the spine, with the left at a greater torque compared to the right. Abnormal coronal plane curvature of the spine resulted in a muscle length imbalance (left side on slack; right side lengthened). This can cause stress on the spinal cord, which can contribute to pain and dysfunction.²

Spinal Cord



Figure 3. Thoraco-lumbar spinal cord reveal.

i. Dura mater protecting the spinal cord. ii. The dorsal root ganglion (A) exposed revealing the dorsal and ventral roots (B), the dorsal rami (C) and the ventral rami (D).

The dorsal and ventral nerves innervate skin regions and transmit both sensation and movement throughout the body. Disruption to any level can lead to predictable sensory loss and motor deficits, which scoliosis patients are at high risk for.³

The Nervous System and Scoliosis

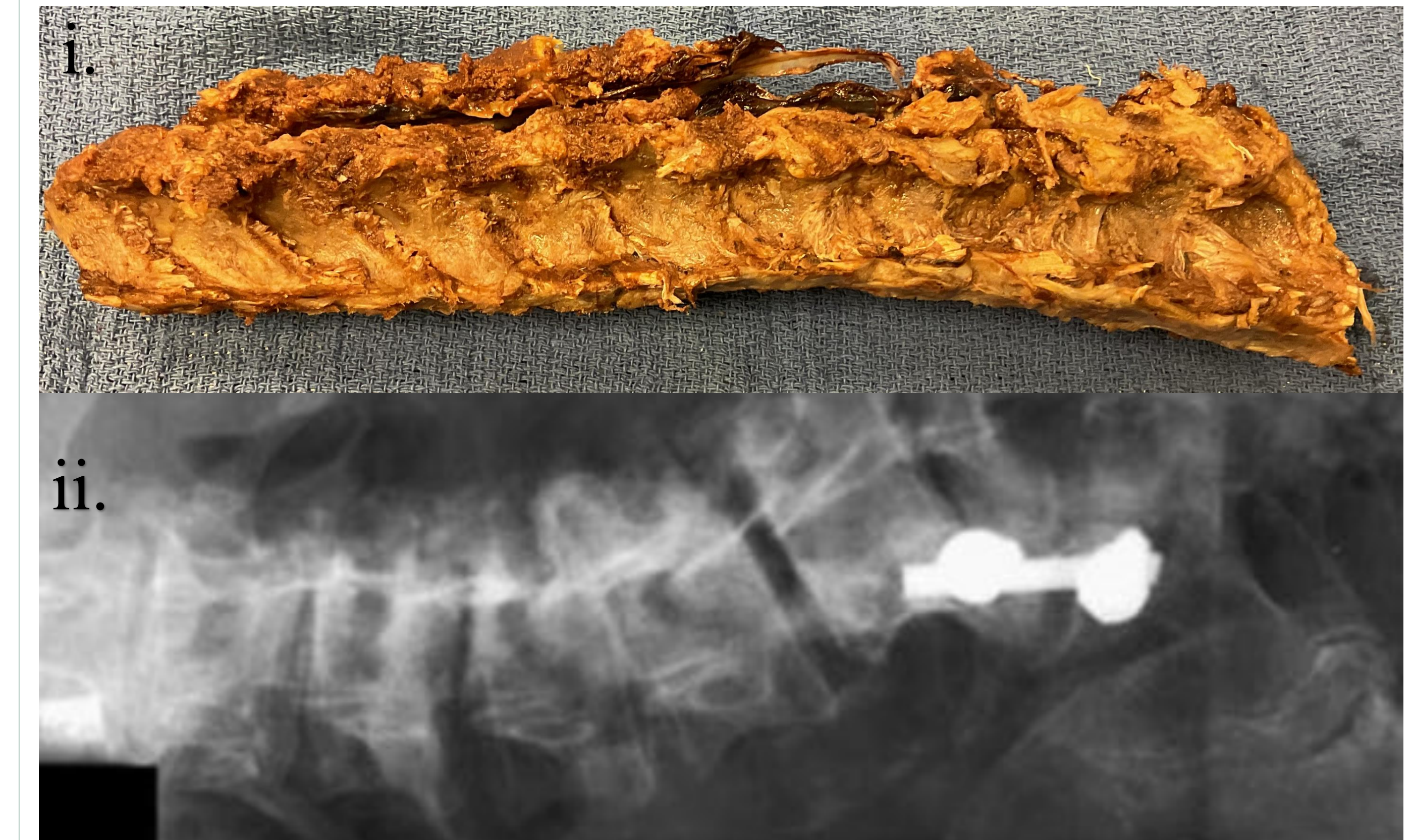

Figure 4. Vertebral Column Removed From the Body.

The vertebral column removed from the body (i). An example of a left fusion to prevent progression of the curvature (ii)⁴

Curvature of the vertebral column places excess pressure on the spinal cord and other structures in the back which can pinch nerves, causing pain and dysfunction in patients. Treatment is important to prevent further damage, including physical therapy, and in some cases surgery to decompress nerves or straighten curvature.⁴

Gait Mechanics and Scoliosis



Figure 5. Phases of a Normal Gait Cycle.

The gait cycle includes two phases, the stance phase (pink: heel strike, mid-stance, toe off) and swing phase (black).⁶

Patients with scoliosis are slower with stride length during gait and must use more physical effort than healthy patients. Altered gait mechanics increases fall risk and decreases quality of life.⁵

References

- ¹Yagi, M., et al. (2021). *Paraspinal muscle activities in S-shaped adolescent idiopathic scoliosis during physiotherapeutic scoliosis-specific exercise: A case-control study.* BMC Musculoskeletal Disorders.
- ²Matheve, T., et al. (2023). The Role of Back Muscle Dysfunctions in Chronic Low Back Pain: State-of-the-Art and Clinical Implications. *Journal of clinical medicine.*
- ³Machida, M., et al. (2018). *Pathogenesis of Idiopathic Scoliosis.* Springer Tokyo.
- ⁴Aebi, M. (2005). The adult scoliosis. *Eur Spine J* 14, 925-948.
- ⁵Haber, C. K. & Sacco, M. (2015). Scoliosis: Lower Limb Asymmetries During the Gait Cycle. *Archive Physiotherapy.* 5, 4.
- ⁶Foot Bionics. (2023). *The Gait Cycle.*